



LINX REFLUX MANAGEMENT SYSTEM: NEW TREATMENT FOR GERD

Zaveri HM MD, Surve AK MD, Cottam DR MD, Richards CG MD, Cottam SD
Bariatric Medicine Institute, Salt Lake City, Utah, USA

INTRODUCTION

- In GERD, the underlying mechanism is Lower Esophageal Sphincter muscle which is either weak or relaxes inconsistently, allowing the content of the stomach to reflux into the esophagus, the airway & the mouth.
- Chronic GERD affects 10% of the western population and has profound negative impact on quality of life.
- Majority of people are treated with PPI, but up to 40% have incomplete relief of symptoms even after the dose adjustment.
- The Lap Nissen fundoplication is surgical gold standard, however the level of technical difficulty & its side effects have limited its use to less than 1% of the GERD population.
- As a consequence, a significant "therapy gap", in the treatment of GERD remains evident in the current clinical practice.
- The LINX Reflux Management System (Torax Medical) is designed to provide permanent solution to GERD, that it allows the augmentation of the strength of lower esophageal sphincter to address underlying mechanical issues with reflux.
- It is safe and effective tool that does not alter gastric anatomy and can be easily reversed if necessary.

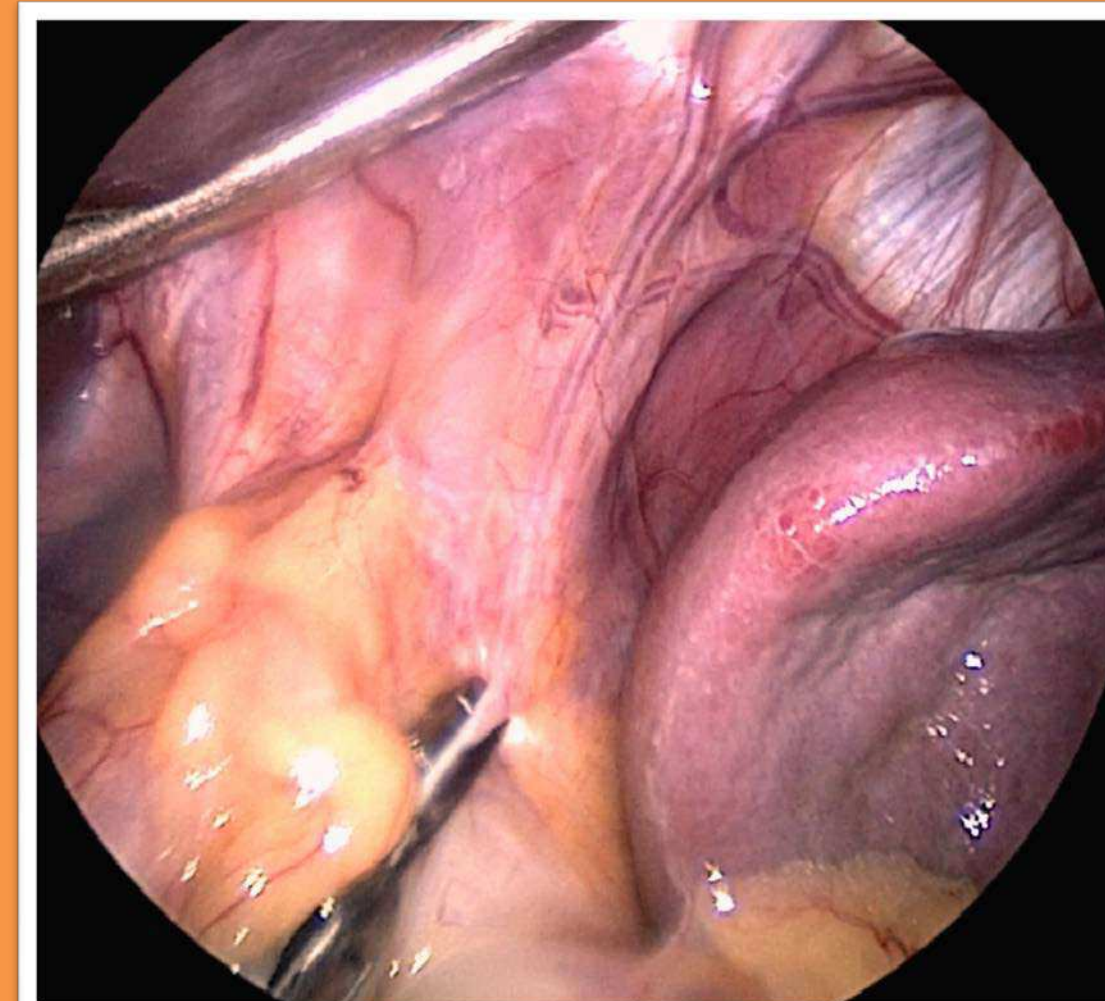
OBJECTIVE

- We present our recent experience with two cases of severe GERD treated by LINX Reflux Management System. We give you the details of the procedure and any complications associated with it.

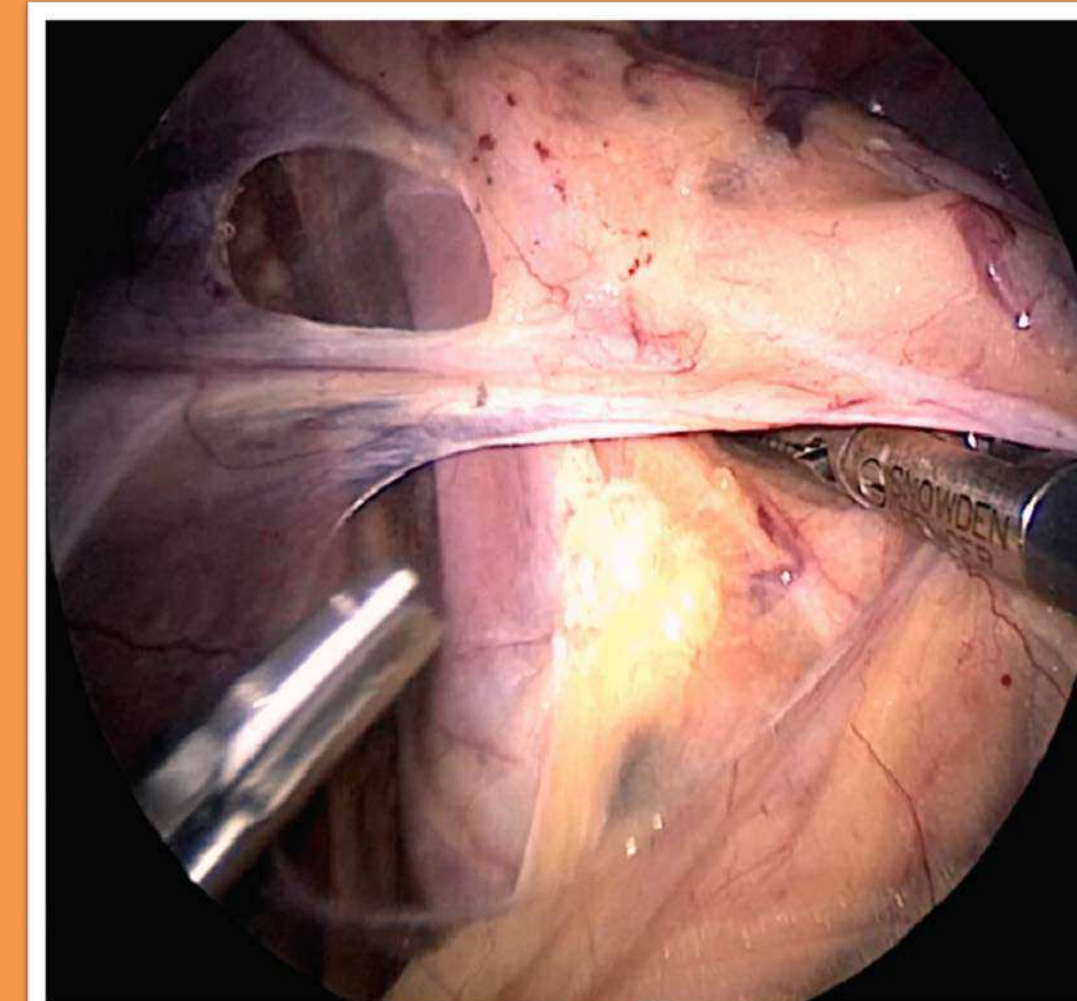
Results- Case #1

- This is 50 y/o female with the h/o laryngopharynx reflux since 10-12 years, who was evaluated for severe GERD. Her symptom gets worse in the night after eating food. She takes Omeprazole 40mg Po QD. She also had atypical symptoms like shortness of breath and hoarseness of voice.
- She was evaluated with esophageal manometry which showed hypotensive lower esophageal sphincter. Impedance showed abnormal reflux and was 100% alkaline. EGD showed normal esophagus and mild gastritis. However she was interested in the possibility of LINX. We discussed that atypical symptoms such as shortness of breath respond less well to the surgery.
- Given the immediacy of symptoms in setting of abnormal esophageal acid exposure, she seemed to be a reasonable candidate for LINX.
- Her operating time was 37mins. There were no intraoperative or postoperative complications. Length of stay in the hospital was 1 day.
- She was evaluated 2 weeks post op at our institution and her GER symptoms had resolved, her atypical symptoms like hoarseness of voice and shortness of breath had improved

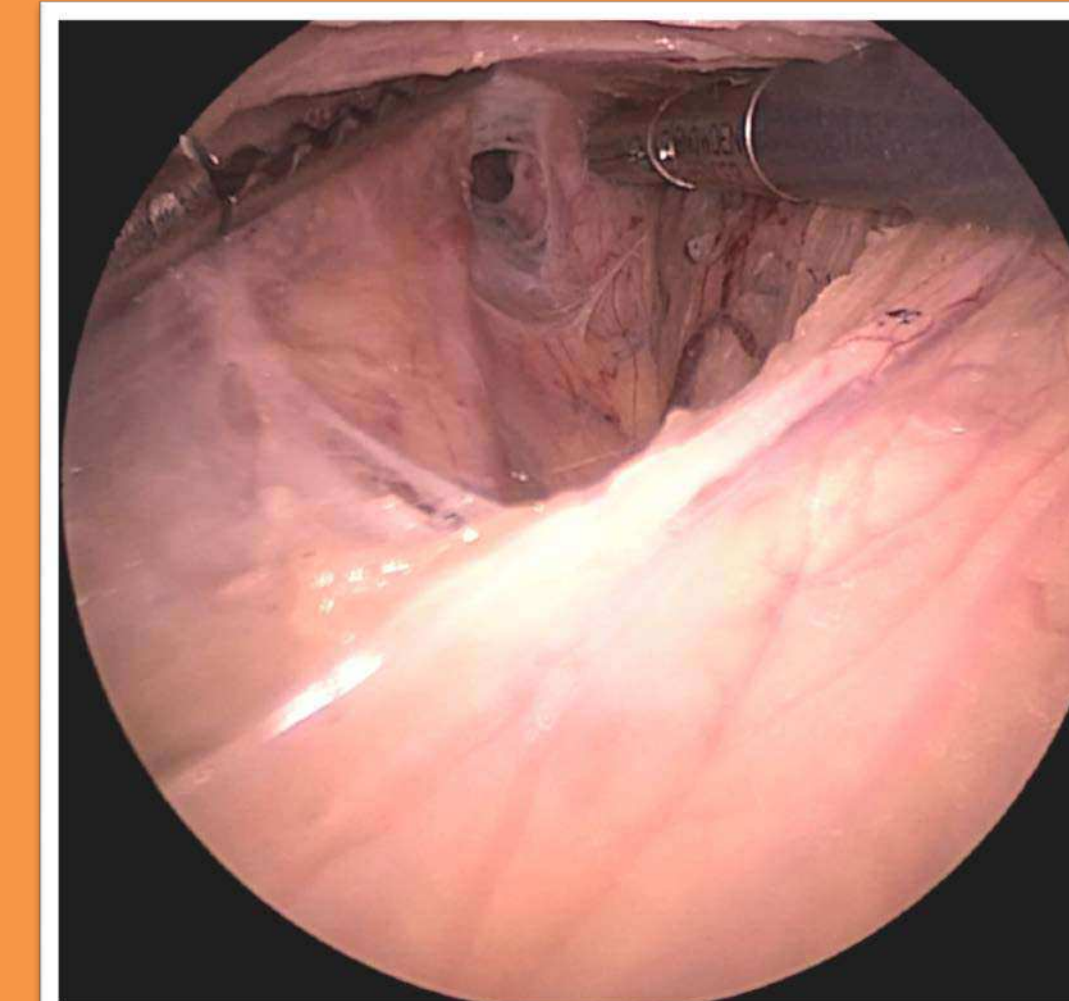
Methods And Procedures



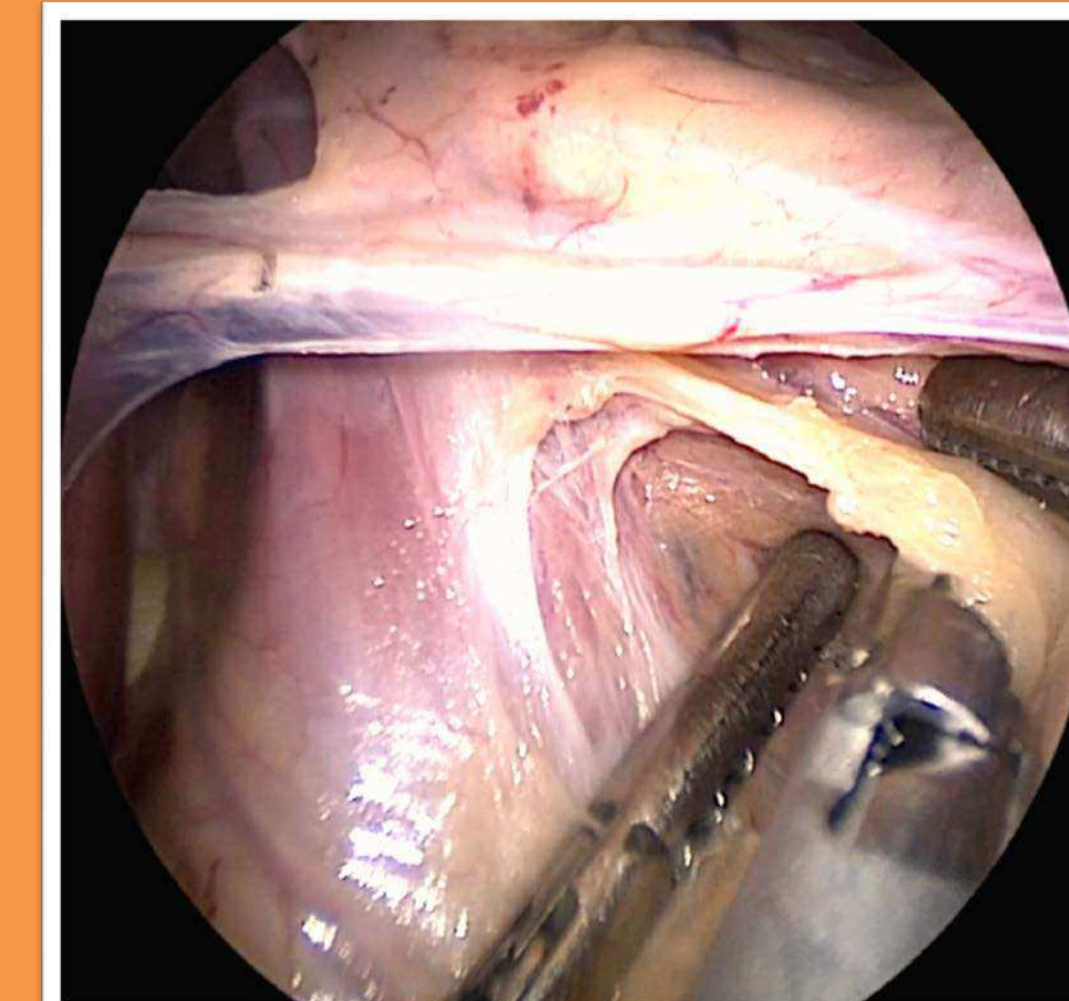
1. Left Bundle of Crus was dissected with Harmonic Scalpel.



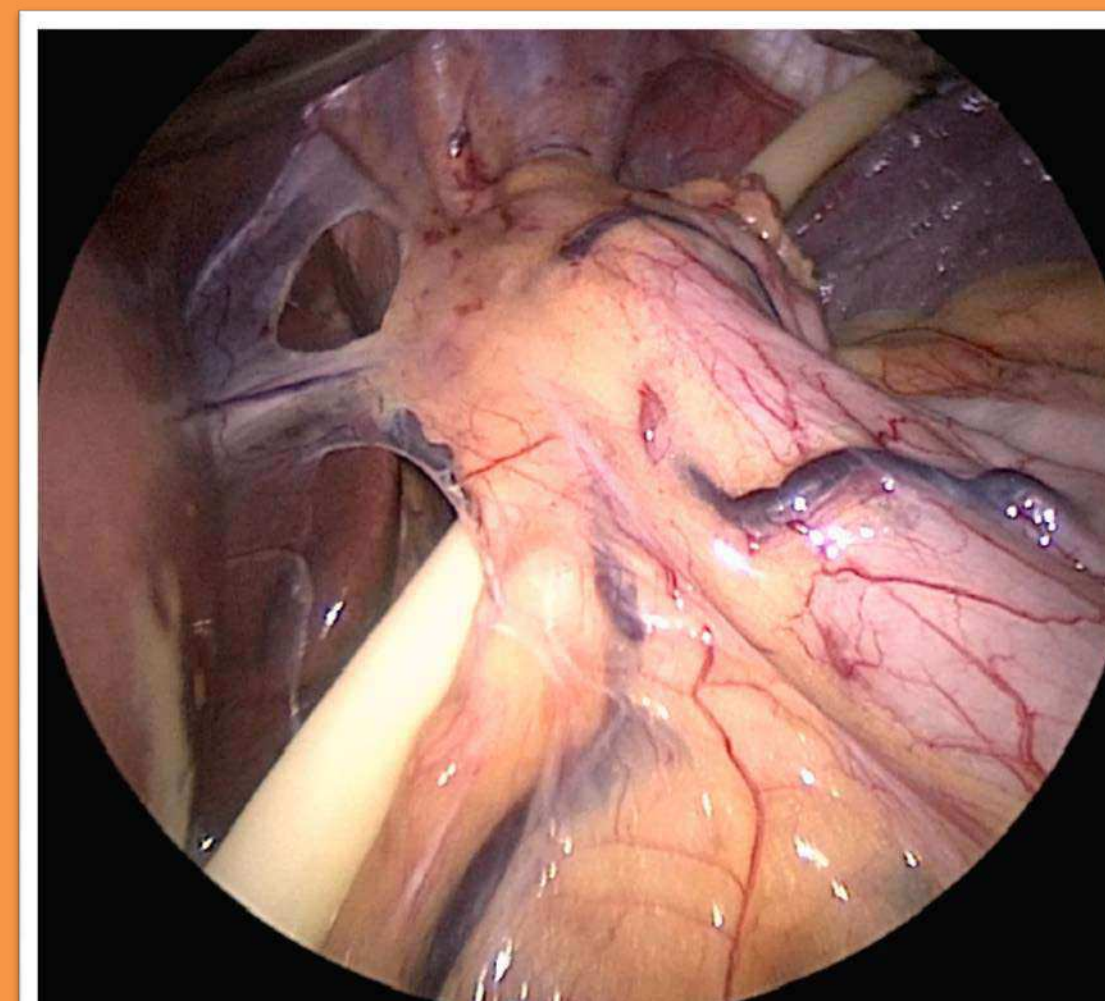
2. Pars Flaccida above & below the hepatic branch of vagus nerve is then opened.



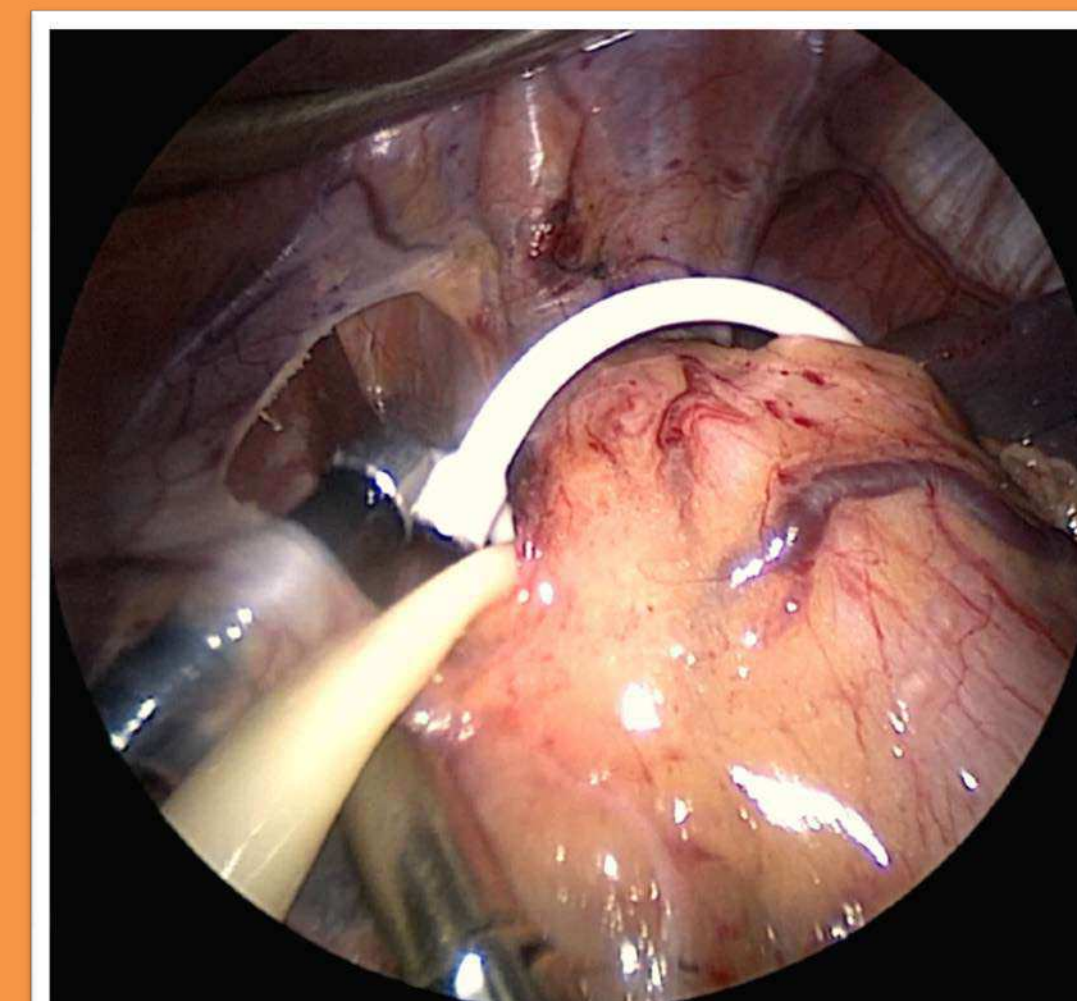
3. Post Vagus Nerve was identified.



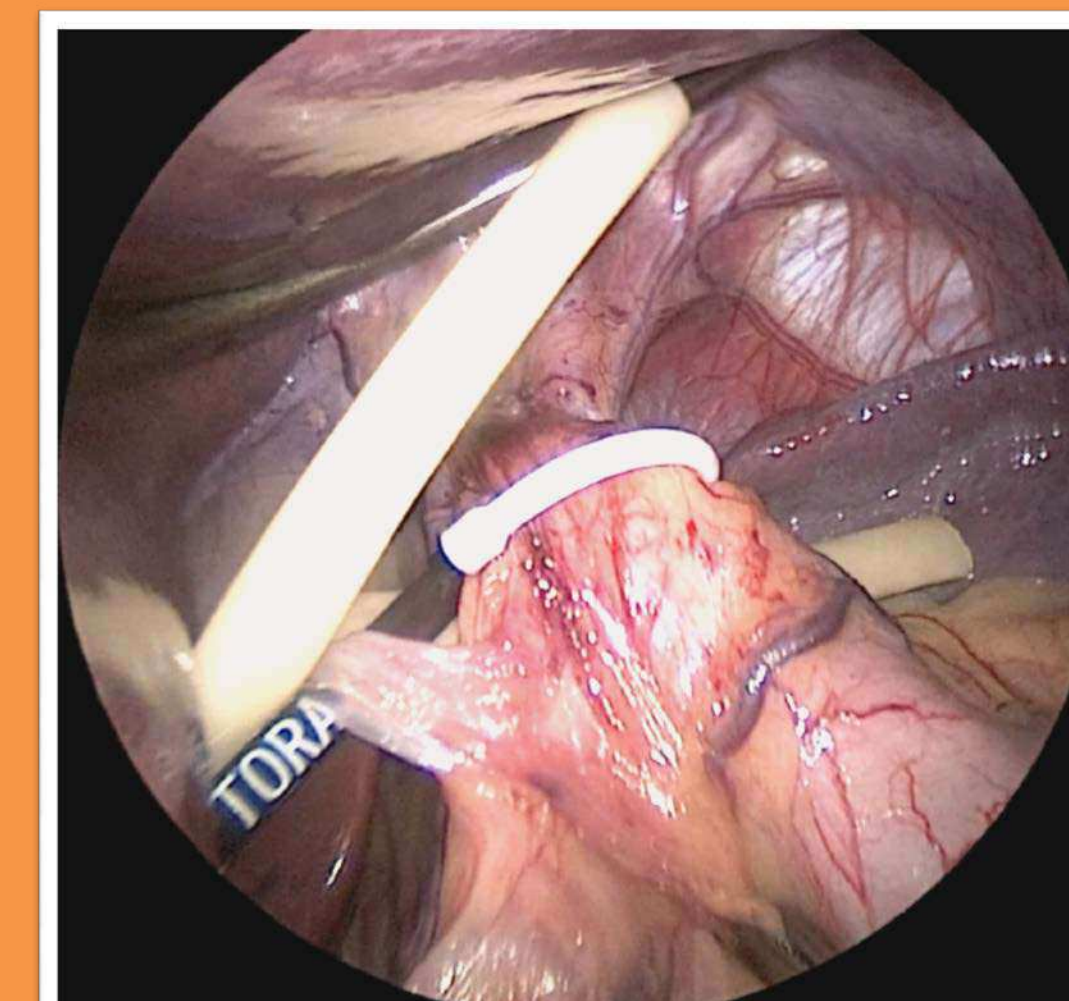
4. Window was made between post Vagus nerve and esophagus.



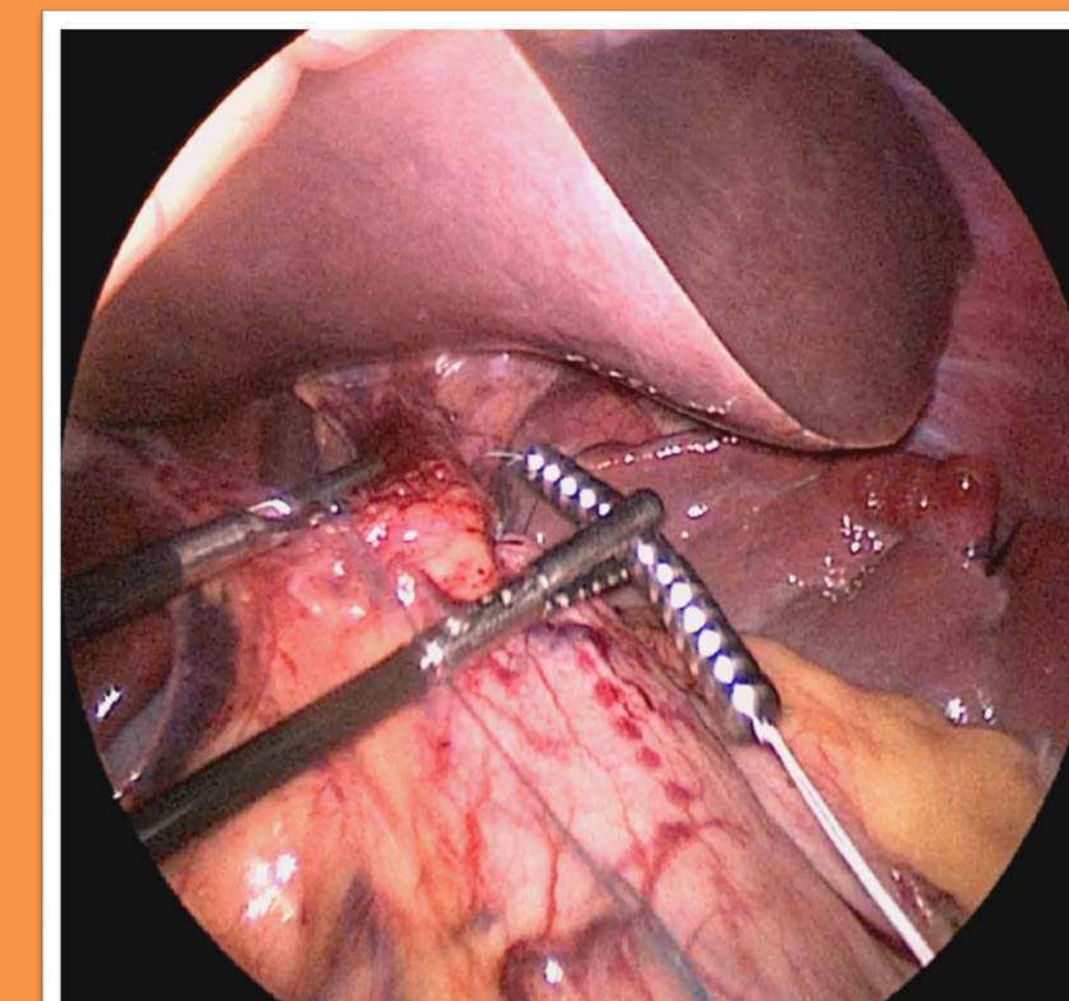
5. A quarter inch Penrose is placed through this tunnel.



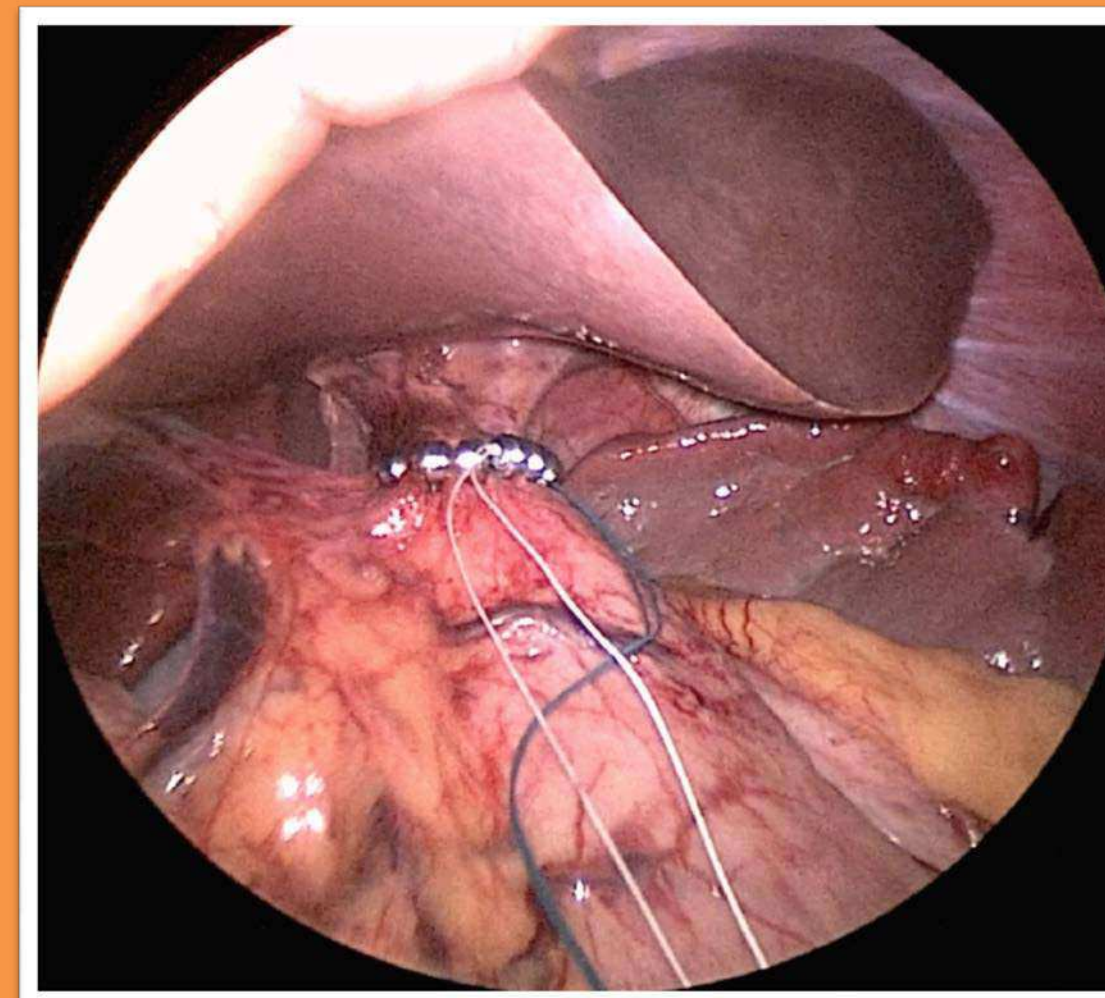
6. Sizing device is introduced and placed through the tunnel.



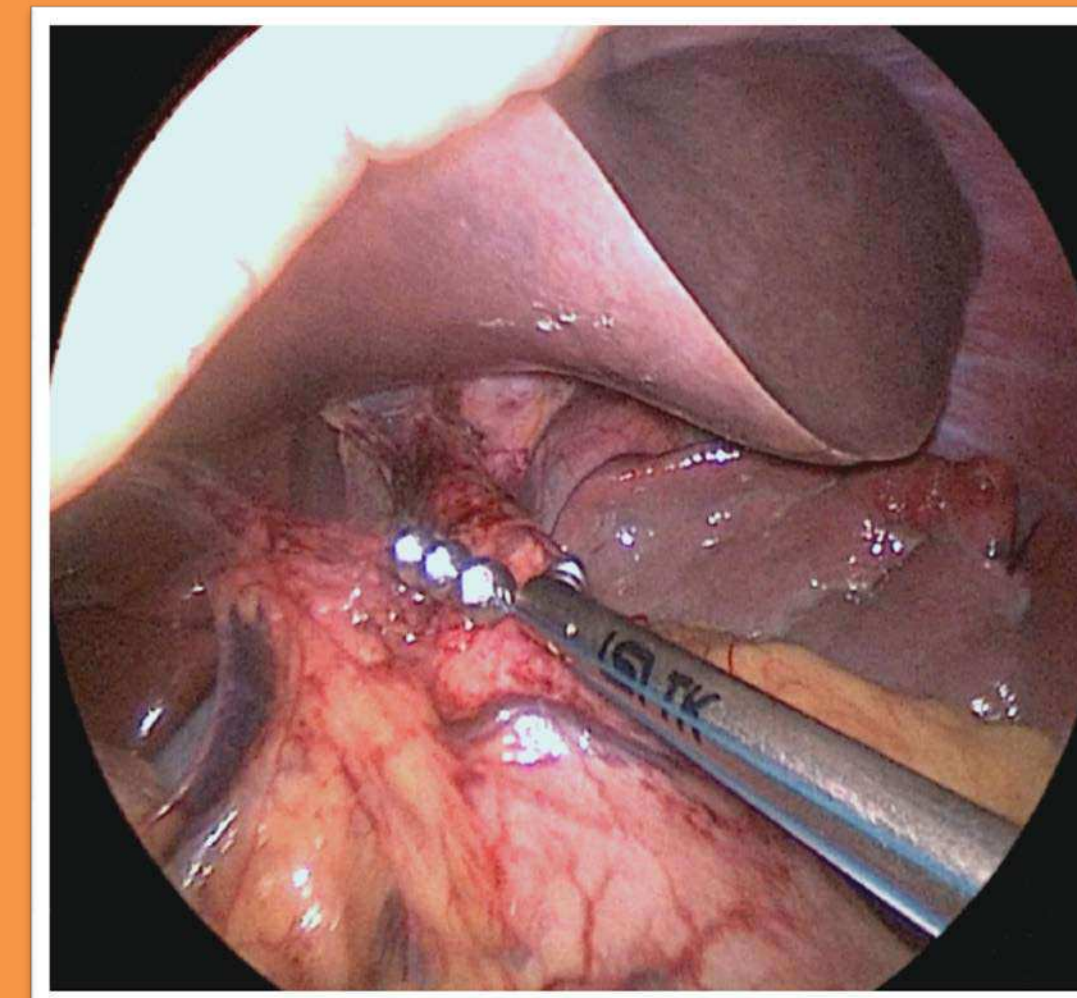
7. It appeared that 13 bead implant would be best fit.



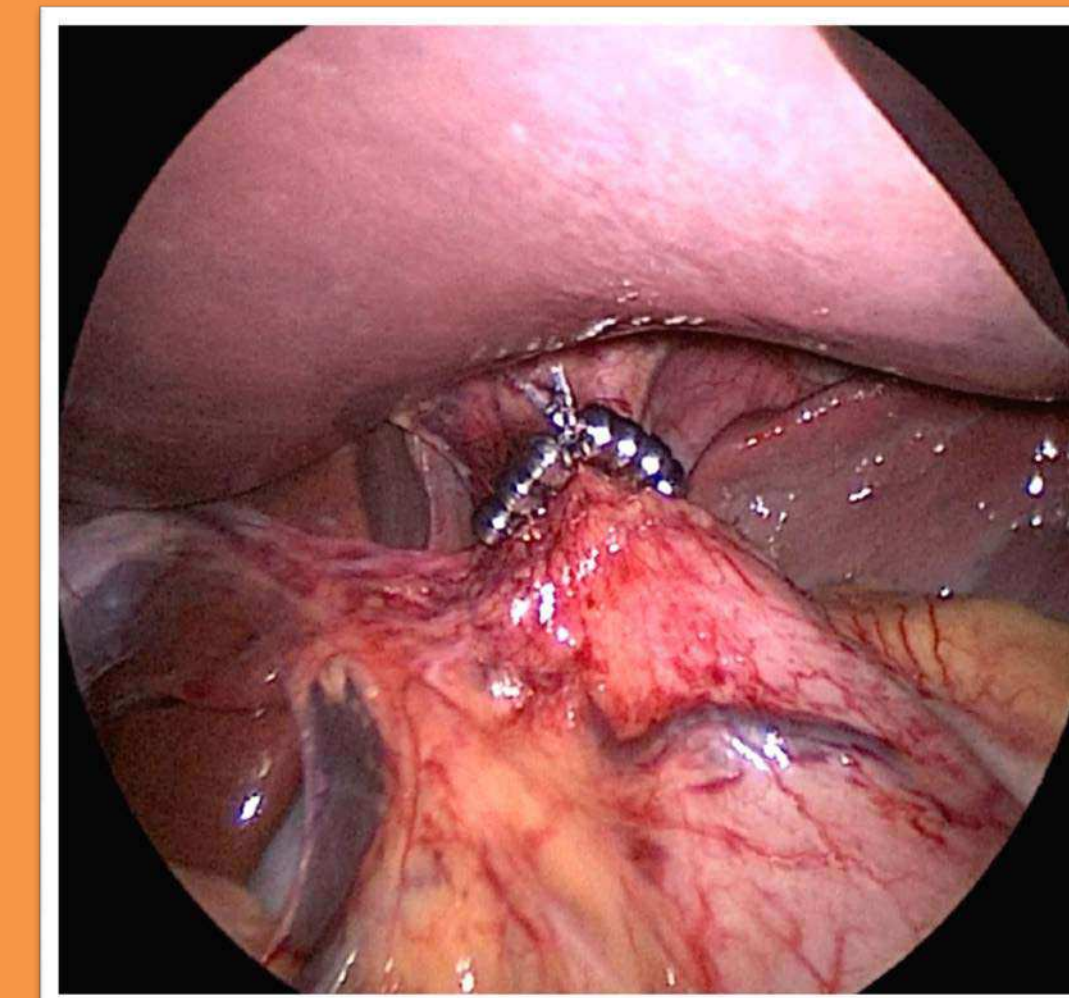
8. Sizer is then removed and LINX device is introduced.



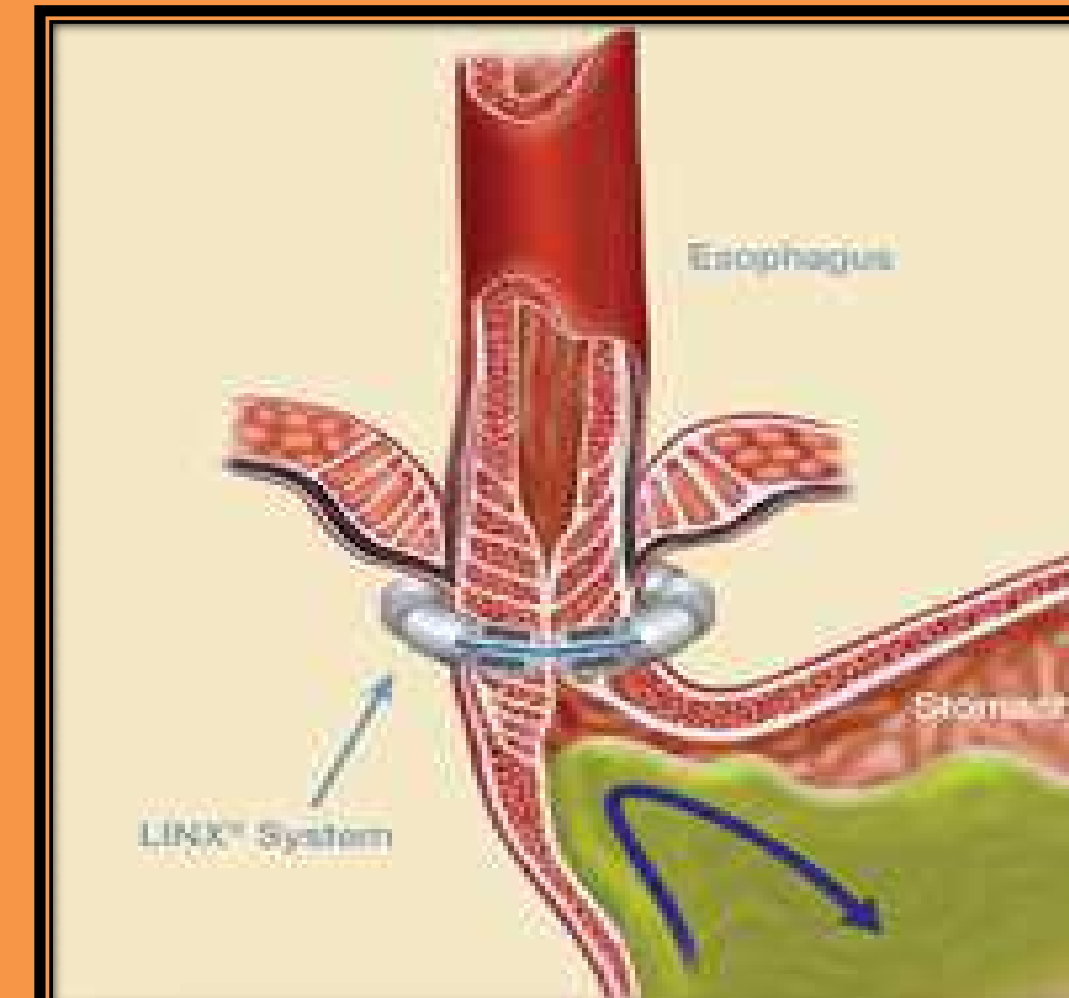
9. The device was then linked.



10. The blue & white sutures were held in place and a fixation device was used to fix the 2 bundles of sutures.



11. There was non-constricting placement of the LINX.

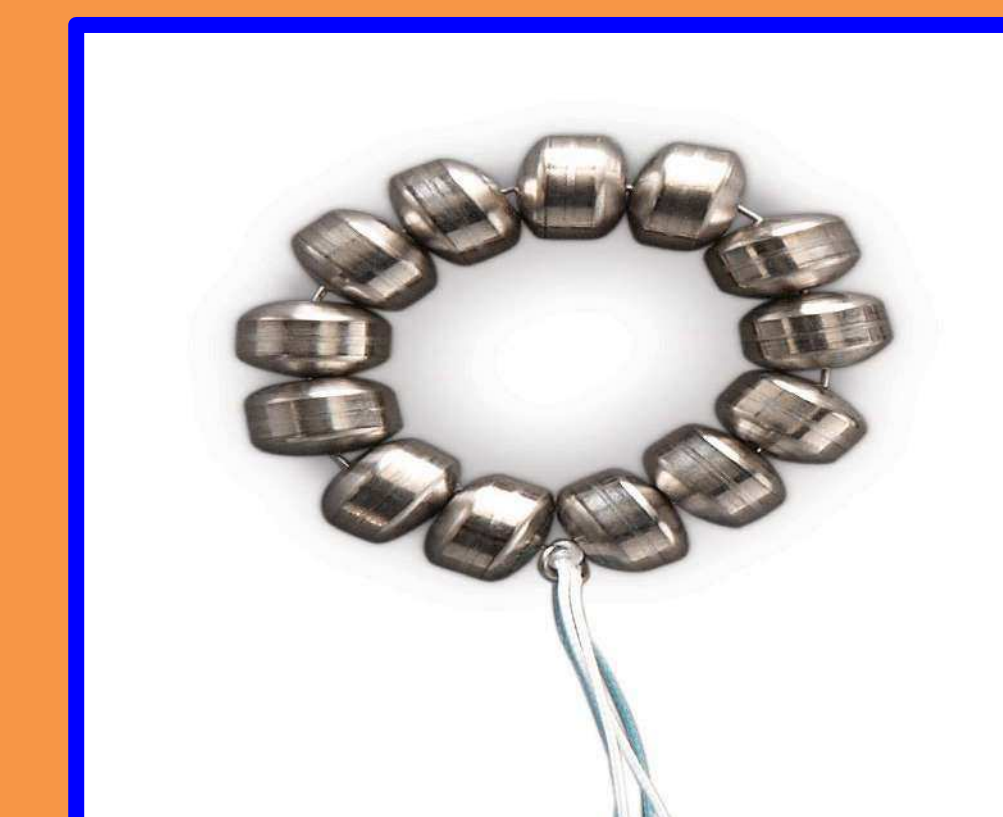


Case #2

- This is 42 y/o male that was evaluated for GERD. He had persistent cough and reflux since 1 year, for which he was started on PPI. However his symptoms became worse thereafter.
- He also c/o irritated throat with metallic taste and sore voice. We tried Protonix but there was no improvement. He made some lifestyle changes but with futile results. At that time he wished to have LINX Surgery.
- His esophageal manometry showed normal pressure lower esophageal sphincter and low amplitude peristalsis. Bravo pH study showed very abnormal acid exposure that correlated good with his symptoms. EGD showed reflux esophagitis and antritis with chronic inflammation but no H.Pylori infection. Pathology was negative for Barrett's esophagus. Looking at his results, he seemed to be a good candidate for LINX procedure.
- His operating time was 32mins. There were no intraoperative or postoperative complications. Length of stay in the hospital was 1 day.
- He was evaluated post op 2 week at our institution, his voice was better. He was belching a lot but there was no reflux.

Conclusion

- LINX is done to treat GERD when medication no longer provides adequate relief.
- It's less invasive, reversible and well tolerated.
- Unless Nissen fundoplication, you don't need dissection of stomach, thus it preserves the ability to vomit and belch after the procedure, which is not always possible. And unlike medicine, it addresses the underlying issue of the valve.
- The maintenance of these good outcomes will be critical to gaining acceptance and reimbursement for this treatment option.
- Studies with larger sample and longer term follow up are needed to confirm these early results and assess long term safety.



Scan the barcode to get the video for this surgery

